Theragnostic Imaging:

Could DW-MRI inform radiotherapy treatment of bladder cancer?

Jane Rogers[1,2], Victoria Sherwood[2], Spyros Manolopoulos[1,2], Jon Duffy[1]

[1] Physics Department, University of Warwick, Coventry CV4 7AL [2] Medical Physics, University Hospitals Coventry and Warwickshire, Coventry CV2 2DX

Background

Diffusion weighted imaging (DW-MRI) is increasingly used to assess tumour burden and treatment response [1].

DW-MRI could also facilitate targeting of radiotherapy to the most aggressive areas of tumours rather than the current practice of uniform treatment - this is *theragnostic imaging* [2]. However inherent geometric distortions mean direct inference of tumour position could introduce unacceptable inaccuracies.

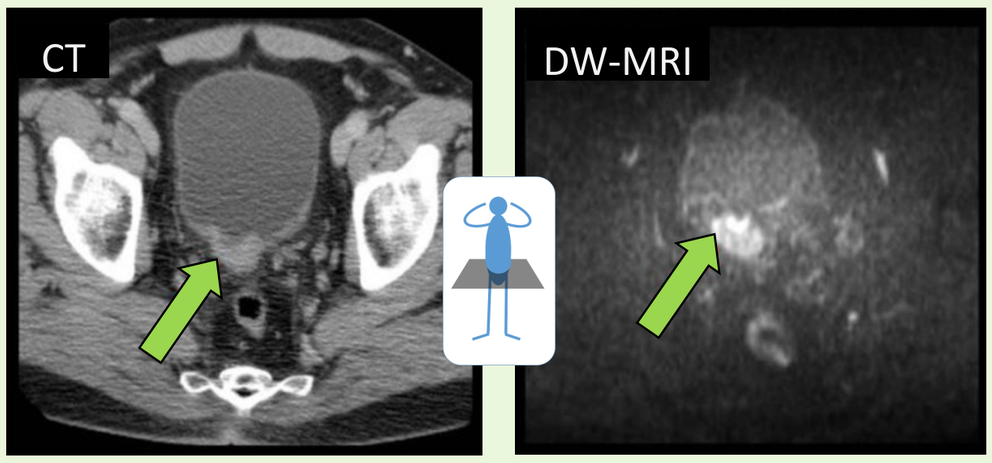

Thickened dorsal bladder wall (CT) and corresponding reduced diffusion in tumour (DW-MRI) [3]

Objectives

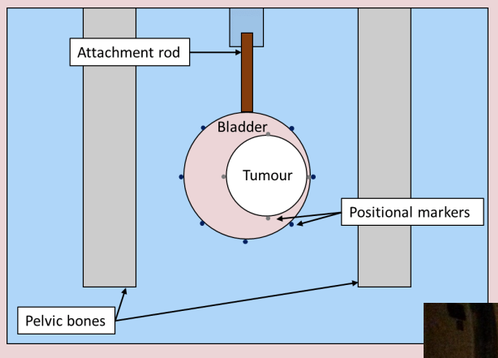

Design and construct a model bladder with tumour.

Image with CT and DW-MRI, and quantify effects of image distortion by measuring positional differences between markers on CT and DW-MR images. Assess deformable registration in RayStation for mitigating effect.

Results

CT and DW-MRIs of model bladder were compared using RayStation with rigid and deformable registrations.

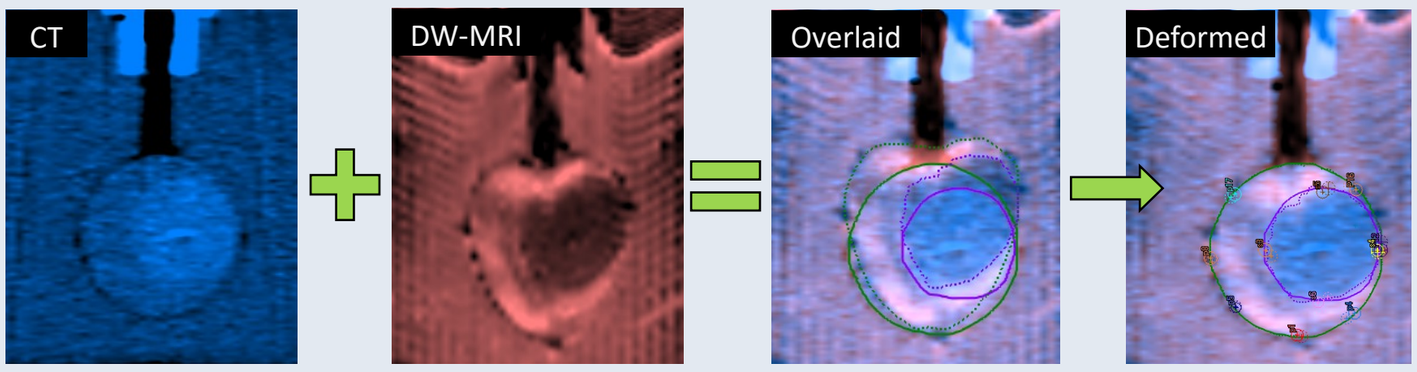

Differences in marker positions were measured for two bladder volumes each with an internal tumour.

	Rigid (mm)		ANACONDA algorithm (mm)						MORFEUS algorithm (mm)			
			Default		IL		Focus ROI		Fixed		Sliding	
Small/Empty Bladder	**6.2**	*± 2.8*	**2.7**	*± 0.8*	**2.9**	*± 0.9*	**2.8**	*± 0.9*	**3.3**	*± 1.4*	**3.0**	*± 1.1*
Tumour	**8.0**	*± 3.1*	**3.2**	*± 0.7*	**3.5**	*± 1.1*	**3.3**	*± 0.9*	**3.4**	*± 1.2*	**3.4**	*± 1.2*
Partially-full Bladder	**4.8**	*± 2.4*	**2.2**	*± 1.1*	**2.4**	*± 1.1*	**2.1**	*± 1.0*	**2.5**	*± 1.2*	**2.3**	*± 1.1*
Tumour	**7.0**	*± 1.5*	**3.0**	*± 1.4*	**2.8**	*± 0.8*	**2.6**	*± 0.8*	**2.6**	*± 0.6*	**2.6**	*± 0.6*

Conclusions

Similar results for all deformable registration options tested. Positional errors were reduced from 5-8 mm down to 3 mm which remain *along* surfaces.



Bladder wall matches better than tumour (as expected). MORFEUS algorithm performs slightly worse than ANACONDA due to intermediate contour-fitting step. Margins of 5 mm are appropriate for next section of work.

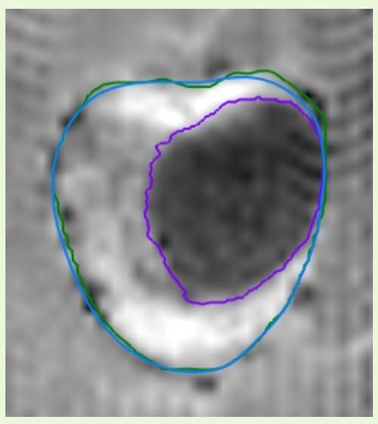

Future Work

Simulate tumours of varying size and position with 5 mm margins; create radiotherapy treatment plans with a range of doses to bladder and tumour.

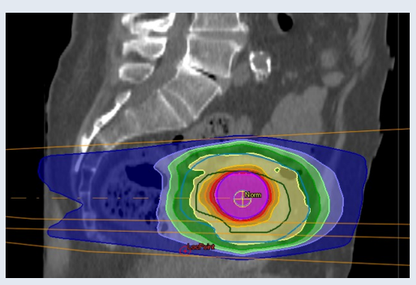

Calculate the potential increase in tumour control probability due to dose escalation from this approach.

References

[1] Malayeri, A. a, El Khouli, R. H., Zaheer, A., Jacobs, M. a, Corona-Villalobos, C. P., Kamel, I. R., & Macura, K. J. (2011). Principles and applications of diffusion-weighted imaging in cancer detection, staging, and treatment follow-up. *Radiographics 31* (6), 1773–91.

[2] Bentzen, S. M. (2005). Theragnostic imaging for radiation oncology: Dose-painting by numbers. *Lancet Oncol.* 6:112-117.

[3] Maurer, T. , Horn, T., Heck, M., Gschwend J. E., Eiber M., Beer A. J. (2013). Current staging procedures in urinary bladder cancer. *Diagnostics* 3, 315—324.

Contact: j.a.rogers@warwick.ac.uk